



By Email

STATE WILDLIFE HEADQUARTERS, ODISHA
OFFICE OF THE PRINCIPAL CHIEF CONSERVATOR OF FORESTS (WILDLIFE) & CHIEF WILDLIFE WARDEN, ODISHA
FOREST, ENVIRONMENT & CLIMATE CHANGE DEPARTMENT, GOVERNMENT OF ODISHA

Memo No. 10252 / 10 WL- CC-57/2024, Dated. 29/08/2024

To

All Divisional Forest Officers (WL) & (T)/
Dy. Director, Similipal (North/ South) WL. Division/
Dy. Director, Nandankanan Zoological Park

Sub:- Standard Operating Procedure for Elephant Endotheliotropic Herpes Virus- Hemorrhagic Diseases.

Apropos to above, I am directed to enclose herewith copy of the Standard Operating Procedure (SOP) for Elephant Endotheliotropic Herpes Virus- Hemorrhagic Diseases prepared by Central Zoo Authority (CZA, 2021), MoEF& CC, Govt. of India which need to be strictly followed while dealing with Herpes Virus of wild elephant in your division.

Encl: As above

Chief Conservator of Forests (WL.)

Memo No. 10253 Date 29/08/2024

Copy forwarded to all the Regional Chief Conservator of Forests & Director, Nandankanan Biological Park for information and necessary action.

Chief Conservator of Forests (WL.)



Standard Operating Procedure for Elephant Endotheliotropic Herpes Virus - Hemorrhagic Disease



CENTRAL ZOO AUTHORITY
Statutory body of the Ministry of Environment, Forest and Climate Change,
Government of India

2021



© pixabay.com

Suggested citation:

Sharma.K.K., Mahato G.,Das.A.K., Zachariah A.,Karikalan.M., Mathur V.,Saini M., (2021) Standard Operating Procedure (SOP) to deal with Elephant Endotheliotropic Herpes Virus - Haemorrhagic Disease. Central Zoo Authority.

EEHV Case Photo Source: College of Veterinary Science, Khanapara and Nandankanan Zoological Park, Odisha
Design: Roopa, Sruthy Boopathy

Acknowledgements

Sincere gratitude is expressed to Dr S P Yadav, Member Secretary, Central Zoo Authority to encourage and support a useful dialogue on a very important but neglected topic. The Drafting Committee members; Dr. K. K. Sarma, HOD, Department of Surgery & Radiology, College of Veterinary Sciences, Guwahati, Dr. Gauranga Mahato, PI of the DBT supported Project Endotheliotropic herpesvirus infection in Asian elephants (*Elephas maximus*) of Assam, India, College of Veterinary Sciences, Guwahati, Dr. A. K. Das, Senior Veterinary officer, Nandankanan Biological Park, Orissa, Dr. Arun Zachariah, Veterinary Officer, Waynad, Kerala Forest Department, Dr. M. Karikalan, Scientist, Centre for Wildlife, ICAR-IVRI, Bareilly, Dr. Vaibhav Mathur, AIG, NTCA and Dr Mrinalini Saini, former Veterinary Consultant, CZA and Dr Gowri Mallapur, Veterinary Consultant, CZA for their valuable inputs and suggestions. Final editing and designing by the technical team at CZA is acknowledged.



Contents

1	Background.....	1
2	Description of disease.....	2
3	Transmission of the disease.....	3
4	Clinical Symptoms	3
5	Post mortem lesions.....	5
6	Diagnosis	5
7	Sample collection	7
8	Treatment.....	8
9	Prevention and control.....	9
10	Vaccination.....	10
11	Monitoring of disease	10
12	Risk period.....	11
13	Introduction of new animal.....	11
14	EEHV infection in pregnant Elephant.....	11
15	Diagnostic centres	12
	EEHV Evaluation Form [OPD card].....	13
	Bibliography.....	17
	Further reading	18

1 Background

“Nature’s great masterpiece, an elephant – the only harmless great thing.”

John Donne, 1572-1631

Elephants have fascinated people for time immemorial. They are integrally woven in our culture and mythology, portrayed in ancient art and often assume positions of reverence amongst people. Elephants inhabit mixed deciduous, evergreen forests, dense tropical rain forests, scrub and grass lands, plain and hilly forests with perennial water sources. In the wild, they are migratory in nature traveling for long distances in search of food and water.

The Asian elephant (*Elephas maximus*) is accorded the highest protection under Schedule I of the Indian Wildlife (Protection) Act of 1972 and categorised under CITES Appendix I. It is a quintessential flagship species, deployed to catalyse a range of conservation goals, including habitat conservation at landscape scales, generating public awareness on conservation issues, and mobilisation as a popular cultural icon both in India and the West. Elephant exhibits are popular in zoos globally and Indian zoos house 86 animals as on today.

Elephant endotheliotropic herpesvirus (EEHV) is a moderately understood emerging disease which can cause a highly fatal hemorrhagic disease when transmitted to young Asian elephants. Though treatable with an early diagnosis and with the rapid application of antiviral drugs, this has only been effective in around a third of cases.

The Central Zoo Authority (CZA), a statutory body of the Ministry of Environment, Forest and Climate Change (MoEFCC), Government of India. As on today, CZA oversees the functioning of 152 zoos and rescue centres across the country. The ensuing Standard Operating Procedure document for Elephant Endotheliotropic Herpesvirus (EEHV) has been compiled by a process of detailed consultation with experts in the field. It is expected to serve as a guidance document to address this dreaded disease.

2 Description of disease

Elephant endotheliotropic herpesvirus (EEHV) is responsible for one of the most devastating viral infectious diseases in elephants worldwide, especially young Asian elephants. EEHV is classified in the family *Herpesviridae*, subfamily *Betaherpesvirinae*, genus *Proboscivirus*, and species *Elephantid beta herpes virus* (<https://talk.ictvonline.org/taxonomy/>) (Kochugal *et al* 2018). It is believed to affect the endothelial tissues found inside the blood vessels. The mortality rate is very high (70-85%) and death occurs within a short period of time (2-4 days).

The prevalence of EEHV in captive Asian elephants in North America and Europe has been well documented. In India, the incidence of EEHV-HD was first reported in 1997. 9 of 15 potential cases were confirmed from Southern India in wild free-ranging calves in Kerala, Karnataka, Tamil Nadu forest reserves, and Madras Zoo (Zhacharia *et al*, 2013). A positive case of EEHV1A infection has also been reported from captive Asiatic elephants of Assam (Barman *et al*, 2017). Within the last 10 years, 59 fatal cases of EEHV disease in Asian elephants have been identified within the eight range countries. Twelve of these deaths were wild elephants (Luz and Howard, 2016).



Fig.1. Lethargy and sternal recumbency



Fig.2. Open mouth breathing

3 Transmission of the disease

The elephants identified as carriers of EEHV need not be isolated from other Elephants. This is because of the fact that most elephants carry EEHV without showing symptoms. In addition, the majority of cases of EEHV-HD have been sporadic. Elephants are social animals and separating them from their herd is likely to increase their stress. However, direct transmission from another acute case cannot be ruled out completely. EEHV is mostly spread through mucosal secretions which include:

- Saliva
- Breast milk
- Nasal secretions
- Vaginal secretions
- Trunk to trunk contacts.

The disease can only affect elephants and is not infectious to humans or other animals. Epidemiology of the disease is still not clear and further research is required on this aspect. Incubation period of the virus is 7-14 days.

4 Clinical Symptoms

EEHV- HD always occurs either in per acute or acute forms and the elephant may exhibit any of the following symptoms:

- Lethargy
- Selective appetite to complete anorexia
- Pyrexia
- Edema of the head and trunk and limb
- Reduced trunk movement
- Lacrimation (sometimes)
- Vesicle formation on the tongue with salivation
- Cyanosis of the tongue, swollen tongue: starting at the tip and moving caudally
- Mild gastrointestinal signs viz distension of abdomen, colic pain, mild diarrhoea or constipation
- Lameness, stiffness of legs
- Nervous symptoms- Staggering gait, drowsiness, unresponsiveness to command, ataxia due to intracranial bleeding or cerebral hypoxia that may lead to death within 24-48 hours.



Fig.3. Edematous swelling of the trunk



Fig.4. Edematous swelling of the temporal region

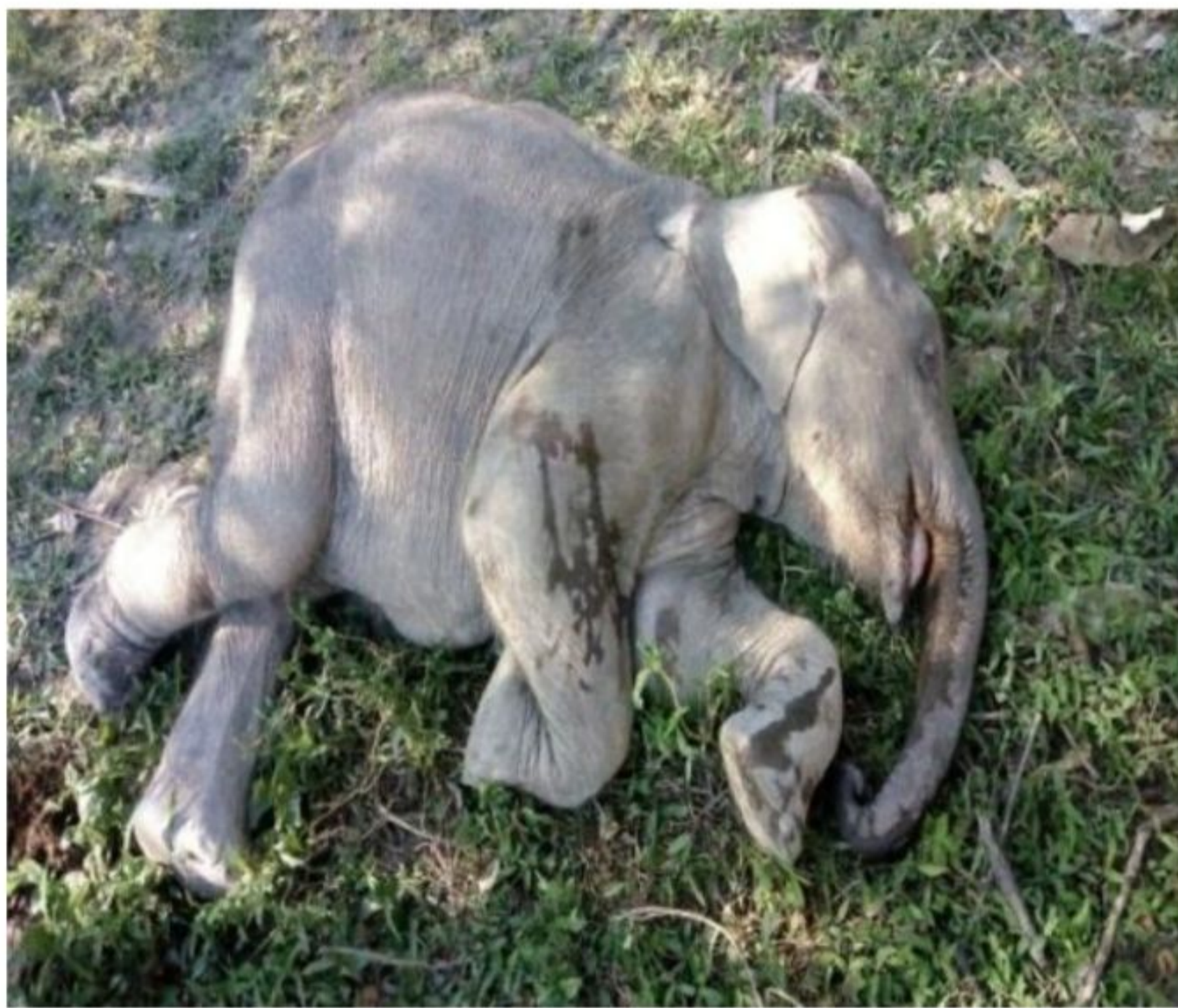

Fig.5. Lateral recumbency

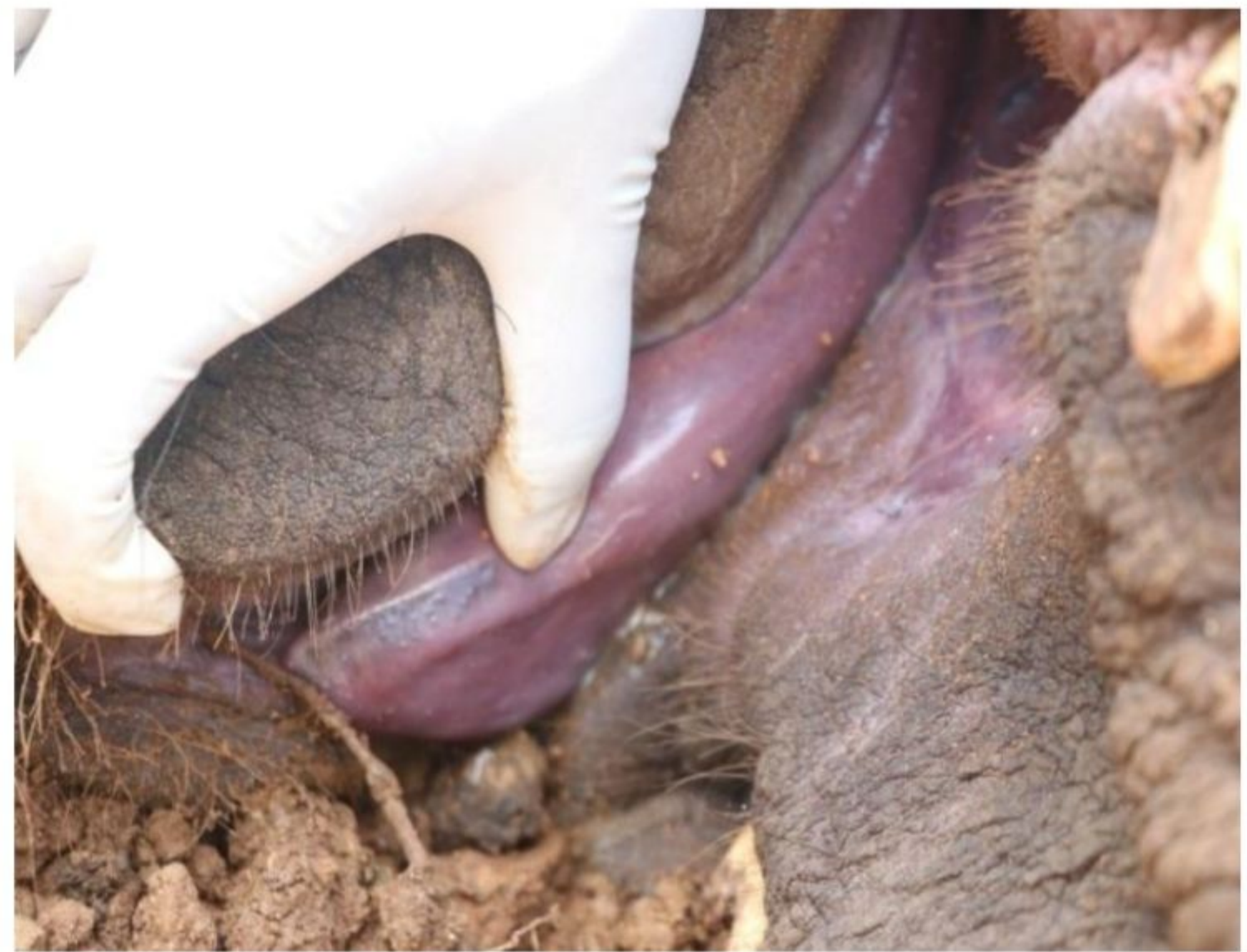

Fig.6. Cyanotic tongue (Blue discolouration of tongue)

5 Post mortem lesions

Post mortem reports generally mention 'Acute Haemorrhagic Disease' in elephants suspected for 'Elephant Endotheliotropic Herpes Virus (EEHV)' infection

Post Mortem findings may include:

- Extensive haemorrhages found in almost all visceral organs
- Purple or cyanotic discolouration of tongue

Histopathology may show: Intranuclear inclusion bodies in endothelial cell lining of visceral organs, particularly in liver sinusoid & spleen

6 Diagnosis

Most elephants carry EEHV latently and show no signs of disease. The disease may cause damage to the lining of small blood vessels, primarily capillaries. When this happens, blood starts to leak out from the vessels. The result is progressive blood and fluid loss. As the damage to the blood vessels worsens, the heart starts to pump less efficiently, and ultimately the elephant dies of shock. The disease can occur at any age group but the elephants that have highest risk are young elephants between the age group of 2-8years.

Confirmation of the disease can be correlated with following factors: -

- Clinical signs combined with the history of the herd,
- Gross post mortem and histopathology findings. Systematic examination of carcasses should be done and the gross lesions will be recorded during post mortem
- Clinical examination of suspected elephants and correlation with parameters like age, sex, temperature, body weight, respiratory rate, heart rate, general demeanour and gait. A detailed history may be collected from the respective forest authorities.
- Differential diagnosis with Encephalomyocarditis virus, Clostridial Enterotoxaemia, Anthrax, Pasteurellosis, Salmonellosis and Hypovitaminosis E.
- Result of Polymerase Chain Reaction (PCR) assays for the detection of EEHV and its subtypes.
- Quantitative real-time polymerase chain reaction (qPCR) assay for confirmation of disease.

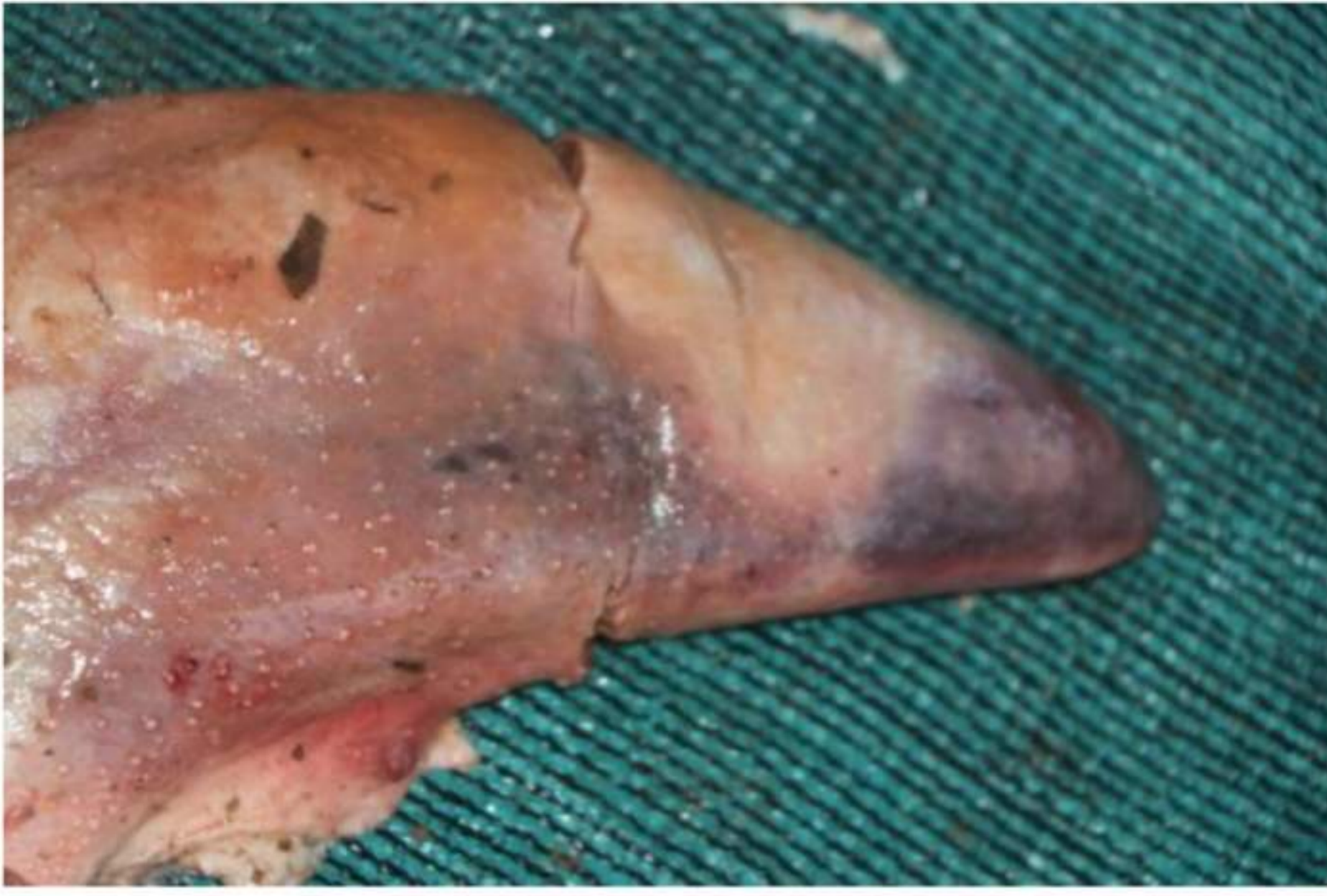

Fig.7. Haemorrhage in tongue

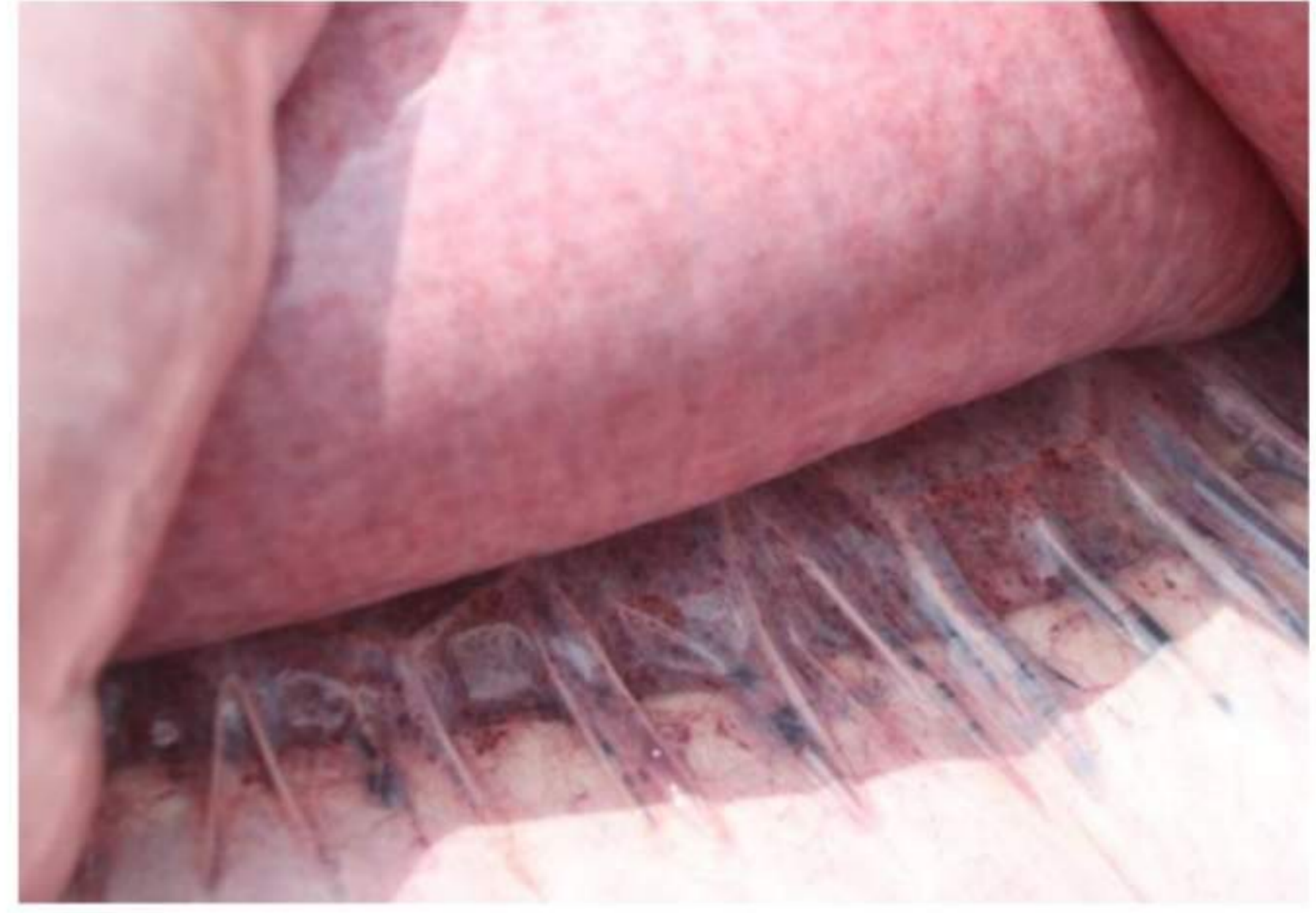


Fig. 8. Haemorrhage in the oral cavity



Fig. 9. Haemorrhage in mesentery

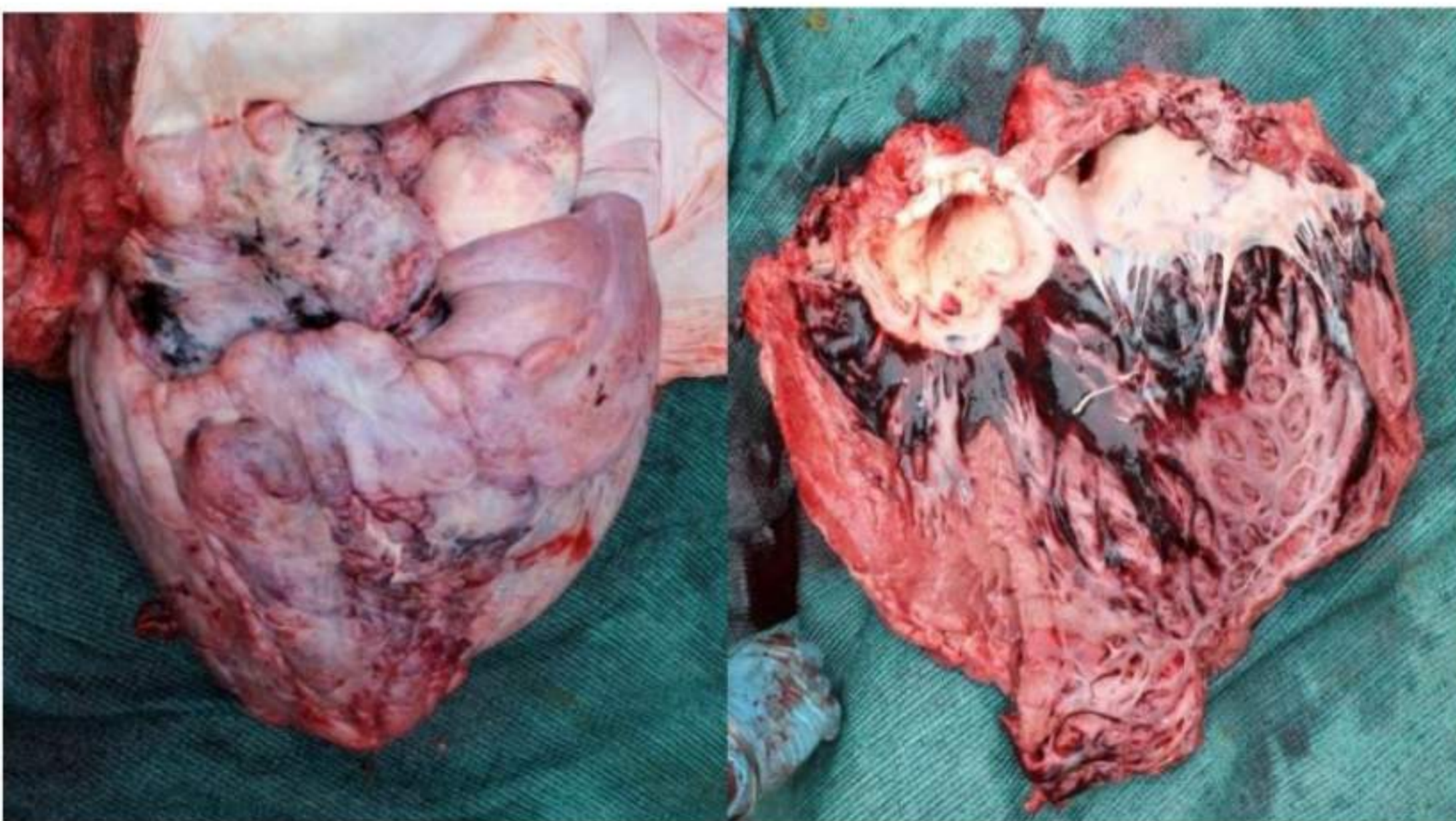
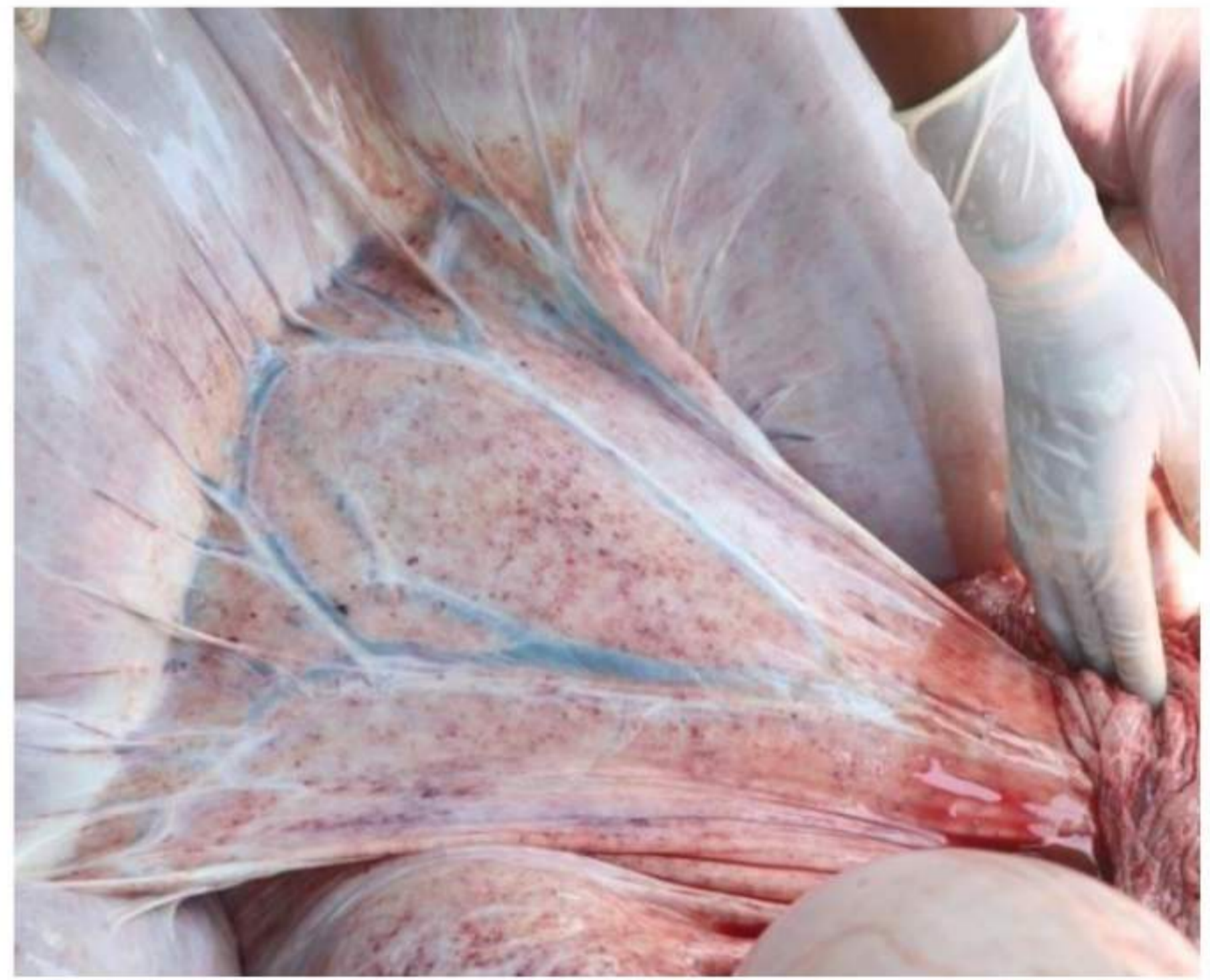

Fig.10. Haemorrhage in heart

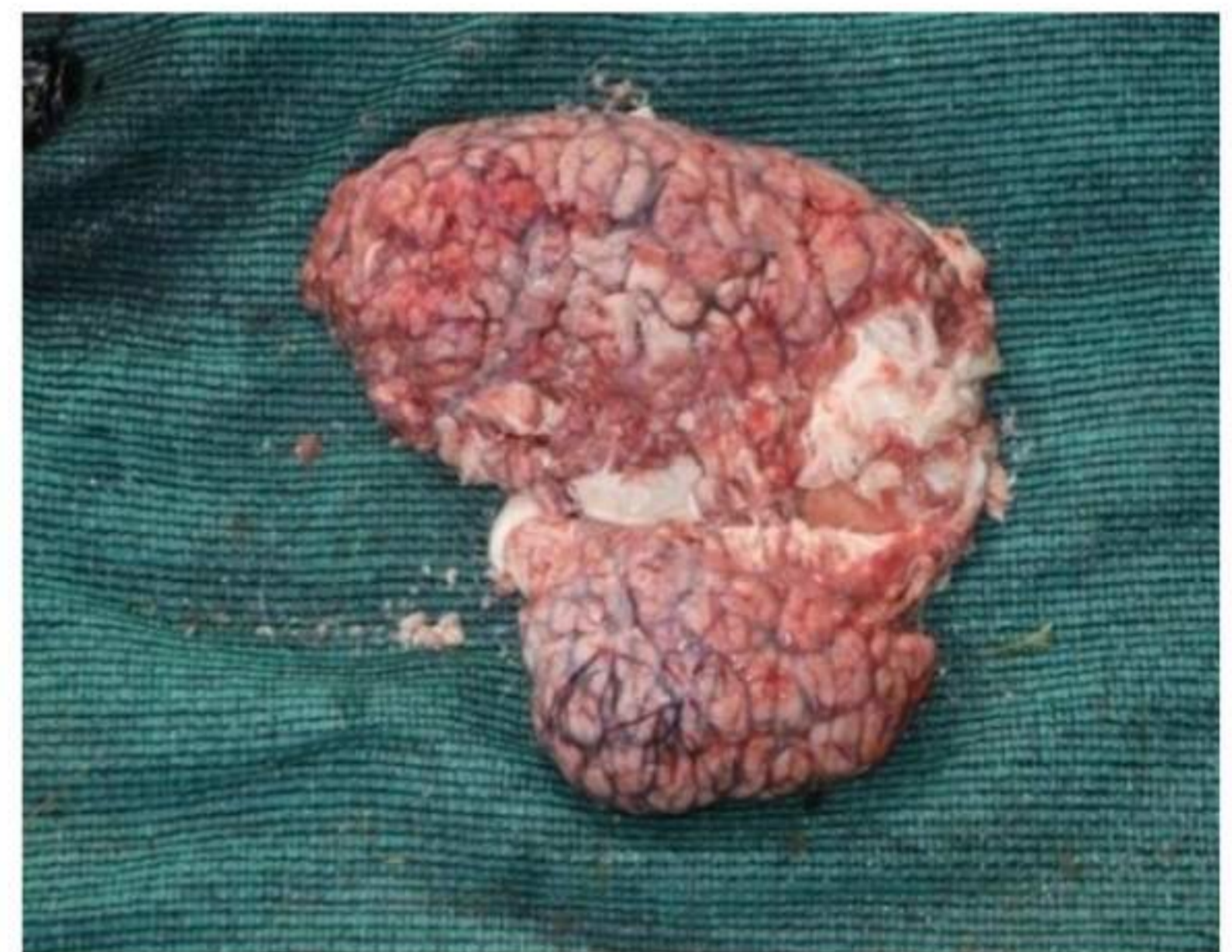

Fig.11. Haemorrhage in brain

7 Sample collection

- a) Samples like blood (whole blood and serum), trunk wash, ocular swabs and faecal swabs may be collected in viral transport media/ Phosphate Buffer Solution (PBS) and transported under cold chain. **Directions for trunk wash collection:** 60 ml sterile saline solution to be infused into trunk, have elephant raise trunk, then collect saline into clean zip-lock bag. Recover minimum of 30 ml of trunk wash fluid. Transfer trunk wash into clean 50 ml conical vials. Centrifuge conical tubes at 900 rpm x 5 min. Carefully remove supernatant without disturbing the pellet. Place equal volume of anti-DNase or anti-RNase solution over pellet. After properly mixing the tube, keep the tube in ice for transportation. Freeze the pellets at -80°C , for storage purpose and processing of sample for later references.
- b) Serum for biochemistry and antibody ELISA testing - Collect blood in red top tube. Keep the tube upright for 5-10 minutes and allow clotting at room temperature. Centrifuge the tube at 1500 rpm for 10 min. gently aspirate out the serum, with the help of pipette. Place the serum (>2ml) into multiple storage tubes. Store the samples at -20°C as soon as possible.
- c) Tissue samples: After post mortem tissue samples like liver, heart, kidney, blood, intestine, tongue, trachea, lung, trunk mucosa, brain, mammary gland, lymph node, oesophagus, urinary bladder, ovary/testis, spleen, uterus, aorta, pancreas, stomach should be collected in Viral Transport Media or in 10 % Neutral Buffered Formalin. The morbid samples submitted directly to the diagnostic centre in cold chain or 10% formalin can also be used.
- d) For Histopathology
Samples from all organs that exhibit haemorrhagic lesions to be collected (Tissue size: 1 cm cube). They may be stored in 10% Neutral buffered formalin at room temperature.
- e) PCR analysis (cPCR and qPCR)
Sample from all organs that exhibit haemorrhagic lesions to be collected. (Tissue size: 1 cm cube). The tissue may be placed in 50 ml conical tube.
- f) Transportation and storage: Place tissue in conical tube with equal volume of 96- 99% alcohol (prefer molecular grade ethanol or HPLC grade ethanol). Transportation should be done in ice. Place -80°C (if not available, -20°C) until the analysis is under process. If 96-99% alcohol is not available, place tissue in regular ethanol and transport under ambient temperature. If alcohol is not available, ship the tissue in conical vial over ice.

8 Treatment

As no vaccines are available as on date, only the elephants identified early with the disease and treated in the early stages have the best chances of survival.

- Treatment should start immediately without waiting for laboratory confirmation.
- Treatment includes two major steps 1) management changes 2) Anti-viral and supportive therapy.
- Treatment should be targeted at causative agent i.e. Herpes virus, supportive care for the animal and controlling secondary bacterial and other infection.
- Sedation: Xylazine 0.04-0.08mg/kg Intramuscular (IM) (can be reversed with Yohimbine or Atipamezole) If insufficient sedation is obtained by Xylazine alone, an additional (low) dose of Ketamine (0.03 – 0.06 mg/kg) can be given IM or Intravenous (IV).

a) Management changes:

- The Elephant should be restrained in a comfortable area free from stress and should be provided with sufficient water, green fodder and concentrates.
- The body temperature should be regularly recorded to assess pyrexia due to viremia.

b) Antiviral drug

- Famciclovir @ 8-15 mg/ kg body weight QID (four times a day) on 1st day and then BID (two times a day) for 3 weeks orally or rectally (Famciclovir is the first drug of choice). In case Famciclovir is not available then Acyclovir can be used with same dose rate and route.
- Rectal administration of anti-viral drug: Generally rectal administration is considered when the elephant declines to accept oral medication because of oral lesion / ulcer and tongue cyanosis. In such cases the calculated doses of antiviral tablets are crushed into powdered form and mixed with ultrasound gel preferably for administration through the rectum.
- In case oral or rectal administration fails then Acyclovir @12.5 mg/kg or Ganciclovir @ 5mg/kg can be given IV in per acute form of sickness.

c) Fluid therapy

- Intravenous and rectal administration of fluid may be required to save the animal from shock.
- The volume of fluid for rectal administration may vary from 10-15 litres depending on the clinical status of the animal @ 20ml per kg body weight.
- Oral/per rectal rehydration or electrolyte (ORS).

- The fluid is usually deposited at the descending part of the colon slowly.
- In early stages, EEHV fluid therapy may be beneficial for cardiovascular support which is essential to prevent multi organ dysfunction. But in terminal stages of EEHV, fluid therapy is unlikely to have same impact under increasing leakage of capillary endothelium exacerbating peripheral and pulmonary edema. However, if no fluid support is given then it may result in shock leading to myocardial hypoxia and death in severe cases.

d) Diuretics:

- Management of peripheral edema has been achieved successfully with use of Furosemide 0.6 mg/ kg body weight route IV or IM QID.

e) Antibiotics:

- To manage secondary bacterial complication, antibiotic therapy should be started like Amoxicillin (11 mg), Ampicilin (8 mg), Ceftiofur (2 mg), Enrofloxacin (2.5-5 mg), Marbofloxacin (2 mg) per kg body weight.

f) Anti-inflammatory drug:

- In EEHV anti-inflammatory are indicated as a part of analgesic regime reducing secondary inflammation resulting from peripheral edema and haemorrhage. Hence, Non-steroidal Anti-inflammatory drug (NSAID) like Meloxicam or Flunixin meglumine @ 0.6 – 0.8mg/Kg body weight may be considered.

g) Other supportive therapy:

- Immuno-modulator like Levamisole-75 may be given S/C (single dose @ 1ml/50 kg). Besides that, administration of Vitamin-C, antioxidant is also considered as a potential supportive therapy.

9 Prevention and control

- Keep the Elephant in a healthy and near natural environment.
- Avoid all kinds of physical, emotional and other stresses to the animal.
- Follow strict healthcare and management protocol: Deworming, vaccination, regular exercise etc.
- Follow positive reinforcement methods to train the younger calves to accept being handled by the veterinary team. They should be trained to allow collection of blood samples, intravenous and intramuscular drug administration etc.
- The elephant handlers should be the responsible persons and they should be keeping constant vigilance on the elephants, particularly the vulnerable animals.

- Keep a ready stock of antiviral medicines in your facility, so that the medication could be started immediately on observing some of the clinical signs. It should be borne in mind that the medication does not cause any harm if the animal turns out to be negative to EEHV.
- Avoid exposure of Asian elephants to African elephants if both are available in your facility
- Separation of young elephant from the herd is not suggested.
- Regular deworming on the basis of faecal examination.
- Provide balanced diet and avoid transportation.
- Routine check-up of blood (CBC and Platelet) and trunk wash/ whole blood for PCR.
- Vitamin-C or Elephant apple or immunostimulant/immunomodulator.

10 Vaccination

- Vaccines are still not available in India. Vaccines developed in US are still under study. Since the virus has many strains and sub strains, the full spectrum of preventive vaccine needs to be developed.

11 Monitoring of disease

Under ideal circumstances, a healthy juvenile elephant should be monitored every week (checking for the presence of EEHV in the blood). This is based on the incubation period of the disease (7-14 days).

- a. Regular close monitoring of animal with regard to visual inspection of different parts of the body mentioned earlier, vital signs and behavioural pattern.
- b. Any subtle changes in the above parameters may immediately be brought to the notice of a veterinarian for prompt investigation and intervention.
- c. Blood sample and trunk wash should be screened at weekly interval against virus through PCR to suspect/confirmed positive elephant.
- d. Existence of carrier or shedder is not uncommon in EEHV infection. Hence such screening protocol should be in place for all zoo/private/camp having captive elephant to identify carrier/ shedder in herd for further bio-security measures.
- e. Blood sample be regularly screened for Complete Blood Count (CBC), serum biochemical analysis to assess any abnormal haematological changes like leucocytosis, monocytosis, lymphopenia and thrombocytopenia along with elevated Blood Urea Nitrogen (BUN), creatinine and liver enzymes.
- f. Manifestation of clinical signs corroborating with other abnormal changes in vital parameters almost confirms EEHV infection, if the animal is previously confirmed

as a carrier. Hence, it is prudent to initiate aggressive treatment as early as possible considering the severity and rapidly damaging effect of the disease course.

12 Risk period

Although the specific predisposing factors that make an elephant clinically sick are as yet not known, stress of different origin are thought to play an important role for EEHV infection. The main period of stress, where there is a potential risk of EEHV infection include;

1. Changes in immune status
2. Orphan calves which are devoid of colostrum and lack maternal antibodies
3. Weaning
4. Pregnancy
5. Translocation of elephants from old to new place
6. Social disharmony or direct introduction of new animal in the herd
7. Pre-pubertal hormonal changes
8. Period of sickness with other diseases

13 Introduction of new animal

- Animals arriving through exchange/ acquisition programme or rescued animal should be properly quarantined before mixing with an existing herd.
- Animal should be quarantined for a period of 6 months at a separate facility with periodical screening of blood sample and trunk wash by PCR besides regular monitoring of vital signs.

14 EEHV infection in pregnant Elephant

As per the current literature, no specific recommendation is available with regards to management of EEHV positive pregnant elephant. But the following points may be considered:

- 1) The pregnant female is outside the vulnerable age (1-10 yrs.) for clinical EEHV infection. Hence it can remain as carrier/ shedder without manifestation of clinical symptoms (Latent stage).
- 2) In such case only periodical monitoring of viral load through q-PCR from the samples like conjunctival swab/ trunk wash/ vaginal wash may be carried out at three-month intervals.
- 3) There is no report available about abortion/ still birth/ any congenital defect in calves with respect to EEHV infection in the mother. In the case of new born the maternal immunity should be kept in mind.

- 4) There's no confirmed report on transplacental transmission of EEHV infection from positive mother to offspring during pregnancy. So, new born calf may be screened on weekly basis for EEHV infection preferably through non-invasive method of sampling like conjunctival swab or trunk wash to assess the presence of infection along with viral load.
- 5) Regular monitoring through visual inspection of behaviour & vital signs in case of calf born from EEHV carrier mother may be carried out.
- 6) On the basis of lab test report & clinical sign antiviral therapy in such calf can be considered.

15 Diagnostic centres

- Till date PCR (cPCR or qPCR) is the main tool for confirmatory diagnosis of EEHV. Hence bio-samples from either clinical or healthy/suspected individual should be screened at nearby diagnostic centres. At present 5 centres in India are equipped for EEHV diagnosis.
 - IVRI, Izatnagar, Bareilly (www.ivri.nic.in)
 - Centre for EEHV project, Assam Veterinary College, Guwahati
 - Centre for Wildlife Health, OUAT, Surya Nagar, Bhubaneswar, Pin-751003, Ph.0674 239 7146 (Email: wildlifehealthodisha@gmail.com)
 - Centre for Wildlife Forensic & Health, Jabalpur (<http://www.ndvsu.org/index.php/departments/school-for-wildlife-forensic-health>)
 - EEHV Diagnostic laboratory, Kerala Forest Department, Wayanad

. *****

EEHV Evaluation Form [OPD card]

OPD. No. _____ Date _____

Elephant's name _____ Microchip No. _____

Sex Male Female Age _____ (month/year) Birth Date _____

Wild born Captive born Hand reared Parent reared

Type of work Zoo Tourism Logging Patrol other _____

Mahout's name _____ Owner's name _____

Address _____

_____ Tel. _____

Weight _____ kg. True Calculated from BOD measurements Estimated

Nutrition status Obese Good Fair Poor

History

Is this elephant still parent-fed? Yes No Unknown Weaning age _____ year

Recent transport Yes No Unknown

When _____ From _____ To _____

Unusual event

- Extreme environmental changes Yes, when _____ No Unknown
- Human-animal interaction Yes, when _____ No Unknown
- Management changes Yes, when _____ No Unknown
- Mahout changes Yes, when _____ No Unknown
- Training procedure changes Yes, when _____ No Unknown
- Herd status changes Yes, when _____ No Unknown
- Others _____

Exposure history Has this elephant been exposed to the following?

- EEHV confirmed cases Yes, when _____ No Unknown
- Other ill animals Yes, when _____ No Unknown

- Wild elephant Yes, when _____ No Unknown

Medical record

- Vaccination history
-

- Deworming history
-

- Previous illness, testing and treatment history
-

Clinical observation

1. Behaviour changes

- Eating Normal Abnormal Not observed
- Drinking Normal Abnormal Not observed
- Defecation Normal Abnormal (constipation / diarrhea) Not observed
- Urination Normal Abnormal Not observed
- Sleeping Normal Abnormal Not observed
- Locomotion Normal Abnormal Not observed
- Activity / play behaviour Normal Abnormal Not observed

2. EEHV related signs

- Blood-shot eyes Normal Abnormal Not observed
- Oral mucosa – Lesion: Present Not present Not observed
- Colour: _____
- Temporal gland swelling Present Not present Not observed
- Head, face or neck swelling Present Not present Not observed
- Mobility / lameness Present Not present Not observed
- Visible skin lesion Present Not present Not observed
- Tongue cyanosis Present Not present Not observed

3. Physical examination

Heart Rate _____ beat/min Pulse _____ time/min

Respiration Rate _____ beat/min

Temp. _____ °C/°F Mucous Membrane _____

Capillary Refill Time _____ second

4. Lesions

Other examination _____

Sample collection

White blood Serum Faeces Trunk Wash Tissue Swab from _____

Other _____

Collected for _____ Date _____

Recommended sample collection for EEHV diagnosis

Aims	Test method	Whole Blood	Serum	Swab	Trunk Wash	Tissue
Presence of virus**	PCR	X		X	X	X
Viral load	qPCR	X				
Haematology		X				
Chemistry			X			
Serology			X			

** In active case of EEHV, blood samples (or tissue samples from dead elephants) are recommended. Swabs and trunk wash are not likely to be positive in an active case, but can be used for monitoring shedders in a herd.

Camp Form

Current visit date _____ Previous visit date _____

Camp's name _____ Address _____

Contact number _____ E-mail: _____

Type of management Zoo Tourism Logging Patrol Other _____

Average work hours per day _____ hours

Number of elephants: Total _____ Babies _____ (newborn to 1 year old)

Young _____ (1-10 years old) Adult _____ (> 10 years old)

Changes in herd status from last visit; (please specify number of animals, location and date)

Birth _____ Death _____ Arrival _____ Departure _____

Feeding system (please specify type and amount of food) _____

Unusual events record (i.e. flooding, drought, disease outbreak) _____

Frequency of your vet visit _____ previous vet visit date _____

Any concerns from your previous vet visit _____

NOTES

Bibliography

- Barman N.N, Choudhury B, Kumar V, Koul M, Gogoi M.S, Khatoon E, Chakraborty A, Basumatary P, Barua B, Rahman T, Das S.K, Kumar S. Incidence of elephant endotheliotropic herpes virus in Asian elephant in India. *Vet. Microbiol.* 2017; 208(9):159–163.
- Luz, S., Howard, L (2016). Elephant Endotheliotropic Herpesvirus (EEHV) in Asia Recommendations from the 1st Asian EEHV Strategy Meeting. Available online <http://elephantcare.org/wp-content/uploads/2017/02/Asia-EEHV-Guidelines-2016.pdf> (access date 2.12.2020)
- Kochagul, V., Srivorakul, S., Boonsri, K. et al. Production of antibody against elephant endotheliotropic herpesvirus (EEHV) unveils tissue tropisms and routes of viral transmission in EEHV-infected Asian elephants. *Sci Rep* 8, 4675 (2018). <https://doi.org/10.1038/s41598-018-22968-5>
- Zachariah A, Zong J.C, Long S.Y, Latimer E.M, Heaggans S.Y, Richman L.K, Hayward G.S. Fatal herpesvirus hemorrhagic disease in wild and orphan Asian elephants in Southern India. *J. Wildl. Dis.* 2013;49(2):383–391

Further reading

- Derived from: 4th EEHV Asia Working Group Meeting & Int'l Seminar on EEHV
28-30th November, 2019; Faculty of Veterinary Science, Assam Agricultural University, Assam,
India.
- Bechert, U.S., Brown, J.L., Dierenfeld, E.S., Ling, P.D., Molter, C.M. and Schulte, B.A., 2019.
Zoo elephant research: contributions to conservation of captive and free-ranging species.
International Zoo Yearbook, 53(1), pp.89-115.
- Sripiboon, S., Ditcham, W., Vaughan-Higgins, R., Jackson, B., Robertson, I., Thitaram, C.,
Angkawanish, T., Phatthanakunanan, S., Lertwatcharasarakul, P. and Warren, K., 2020.
Subclinical infection of captive Asian elephants (*Elephas maximus*) in Thailand with elephant
endotheliotropic herpesvirus. Archives of Virology, 165(2), pp.397-401. Zaw Min Oo, Ye Htut
Aung, Tin Tun Aung, Nyo San, Zaw Min Tun, Gary S. Hayward, Arun Zachariah. (2020)
Elephant Endotheliotropic Herpesvirus Hemorrhagic Disease in Asian Elephant Calves in
Logging Camps, Myanmar. *Emerging Infectious Diseases* 26:1, pages 63-69.
- Zachariah, A., Sajesh, P.K., Santhosh, S., Bathrachalam, C., Megha, M., Pandiyan, J., Jishnu,
M., Kobragade, R.S., Long, S.Y., Zong, J.C. and Latimer, E.M., 2018. Extended genotypic
evaluation and comparison of twenty-two cases of lethal EEHV1 hemorrhagic disease in wild
and captive Asian elephants in India. PloS one, 13(8), p.e0202438.





© Lakshminarasimha R
National Zoological Park, New Delhi

CENTRAL ZOO AUTHORITY

B-1 Wing, 6th Floor, Pandit Deen Dayal Antyodaya Bhawan,

CGO Complex, Lodhi Road,

New Delhi - 110003

Email: cza@nic.in

Tel: +91-011-24367851/52

